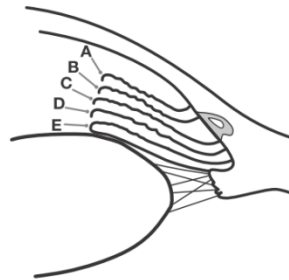


Document the insertion level of the iris root before and during compression dynamic gonioscopy

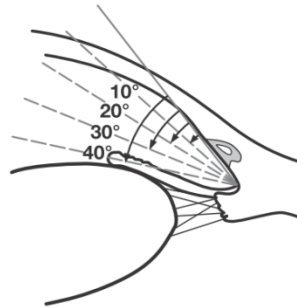
1



Insertion of iris root

- A Anterior to Schwalbe's line
- B Behind Schwalbe's line
- C On the Scleral Spur
- D Behind the Scleral Spur
- E On the Ciliary Band

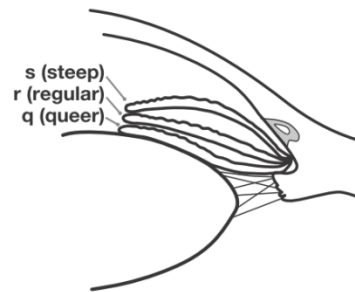
2



Angular width of angle recess

- Slit
- 10° } narrow
 - 20° }
 - 30° } wide
 - 40° }

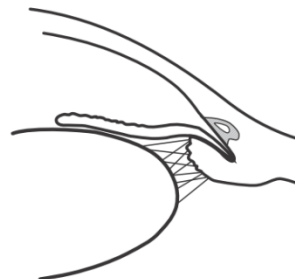3



Configuration of the peripheral iris

- s Steep, anteriorly convex
- r Regular
- q Queer, anteriorly concave

4



Plateau Configuration

Figure 1.5. The Spaeth Grading System of gonioscopy finding